

Browser tabs: (45 unread) - rtungadi@yahoo.co... x

Address bar: mail.yahoo.com/d/search/name=Editor%2520AJPCR&emailAddresses=editorajpcr%2540gmail.com&emailAddresses=editor%2540ajpcr.com&listFilter=FRO...

Page title: Editor AJPCR

Navigation bar: HOME MAIL NEWS FINANCE SPORT ENTERTAINMENT LIFESTYLE WEATHER TV MORE...

Search bar: Editor AJPCR Add keywords

User profile: robert

Compose button

Left sidebar:

- Inbox (45)
- Unread
- Starred
- Drafts (12)
- Sent
- Archive
- Spam
- Deleted Items

Message list:

- [AJPCR] 27747 Yahoo/Inbox

Message details:

From: editor ajpcr <editorajpcr@gmail.com> To: Robert Tungadi

Date: Wed, 6 June 2018 at 1:39 pm

Body:

Dear Author,

We have received your manuscript. Your paper is under review. We will tell you the decision as soon as we receive the comment from the reviewer within 20 days.

Thanks & Regards

Asian journal of Pharmaceutical and Clinical Research

Taskbar:

- Windows Start button
- Taskbar icons: File Explorer, Microsoft Word, Google Chrome, Adobe Photoshop, Microsoft Excel, Microsoft PowerPoint, Microsoft Edge, Google Chrome, Adobe Reader
- System tray: 6:21 PM 11/24/2021

Browser tabs: (45 unread) - rtungadi@yahoo.co... x

Address bar: mail.yahoo.com/d/search/name=Editor%2520AJPCR&emailAddresses=editorajpcr%2540gmail.com&emailAddresses=editor%2540ajpcr.com&listFilter=FRO...
Apps UDDT-Submission [New Tab] Sistem Informasi M... Reading list

Navigation bar: HOME MAIL NEWS FINANCE SPORT ENTERTAINMENT LIFESTYLE WEATHER TV MORE...

Header: yahoo!mail Editor AJPCR Add keywords robert

Compose

Inbox 45
Unread
Starred
Drafts 12
Sent
Archive
Spam
Deleted Items

Actions: Back, Archive, Move, Delete, Spam, ...

From: editor ajpcr <editorajpcr@gmail.com> To: Robert Tungadi
Date: Wed, 27 June 2018 at 6:28 pm

Dear Author,


- Put two citations from IJPPS
- Need to reduce grammatical mistakes
- Introduction is too big need to reduce.
- citation are required as per format and don't put on the heading
- Referencing is required as per format.

Windows taskbar: 7:11 PM 11/24/2021

(45 unread) - rtungadi@yahoo.c... x

mail.yahoo.com/d/search/name=Editor%2520AJPCR&emailAddresses=editorajpcr%2540gmail.com&emailAddresses=editor%2540ajpcr.com&listFilter=FRO...
Apps UDDT-Submission [New Tab] Sistem Informasi M... Reading list

HOME MAIL NEWS FINANCE SPORT ENTERTAINMENT LIFESTYLE WEATHER TV MORE...

yahoo!mail Editor AJPCR Add keywords 

robert

Compose

Inbox 45
Unread
Starred
Drafts 12
Sent
Archive
Spam
Deleted Items

← Back ↶ ↷ ➡ Archive ↗ Move 🗑 Delete 🛡 Spam ⋮ ⌵ ⌶ ✕ 📅 24

citation are required as per format and don't put on the heading

Referencing is required as per format.

Editing and formatting is required as per journal

Please add two citations from our other journal IJPPS Highlight With Red Colour And also add two points CONFLICTS OF INTERESTS or AUTHORS CONTRIBUTION.

There is no need of structural abstract in a review article.

Thanks & Regards

Asian journal of Pharmaceutical and Clinical Research
<http://innovareacademics.in/journals/index.php/ajpcr>

Windows taskbar: 7:11 PM 11/24/2021

Browser tabs: (45 unread) - rtungadi@yahoo.co.id

Address bar: mail.yahoo.com/d/search/name=Editor%2520AJPCR&emailAddresses=editorajpcr%2540gmail.com&emailAddresses=editor%2540ajpcr.com&listFilter=FRO...

Navigation bar: HOME MAIL NEWS FINANCE SPORT ENTERTAINMENT LIFESTYLE WEATHER TV MORE...

Header: yahoo!mail Editor AJPCR Add keywords robert

Compose button

Left sidebar: Inbox (45), Unread, Starred, Drafts (12), Sent, Archive, Spam, Deleted Items

Toolbar: Back, Archive, Move, Delete, Spam, etc.

Email list item: status/AJPCR/27747/18/MM 4 Yahoo/Inbox

Email details:

- From: editor ajpcr <editorajpcr@gmail.com>
- To: Robert Tungadi
- Date: Thu, 28 June 2018 at 5:01 pm

Dear Sir/Madam,

Please read the mail carefully

Your manuscript AJPCR/27747/18 IS REQUIRED entitled "THE EFFECT OF SEA CUCUMBER (HOLOTHURIA SCABRA) EXTRACT AS HEPATOPROTECTIVE: HISTOPATHOLOGICAL STUDY." has been recommended for publication in AJPCR in upcoming issue. The payment details and revision

Taskbar: Windows, Office apps, Browser, File Explorer, etc. 7:12 PM 11/24/2021

(45 unread) - rtungadi@yahoo.c... X

mail.yahoo.com/d/search/name=Editor%2520AJPCR&emailAddresses=editorajpcr%2540gmail.com&emailAddresses=editor%2540ajpcr.com&listFilter=FRO...
Apps UDDT-Submission |... New Tab Sistem Informasi M... Reading list

HOME MAIL NEWS FINANCE SPORT ENTERTAINMENT LIFESTYLE WEATHER TV MORE...

yahoo!mail

Editor AJPCR Add keywords

robert

Compose

Inbox 45

Unread

Starred

Drafts 12

Sent

Archive

Spam

Deleted Items

← Back ↶ ↷ ➡ Archive ↗ Move 🗑 Delete 🛡 Spam ⋮ ⌵ ⌶ ✕ 📅 24

*Please read the mail carefully *

Your manuscript AJPCR/27747/18 IS REQUIRED entitled "THE EFFECTOF SEA CUCUMBER (HOLOTHURIA SCABRA) EXTRACT AS HEPATOPROTECTIVE: HISTOPATHOLOGICAL STUDY." has been recommended for publication in AJPCR in upcoming issue .The payment details and revision points are given below . Please read the details and payment required carefully .

Important:-

Authors are requested to make revision point to point and very strictly.
Failure may cause its rejection.

Windows Taskbar

7:12 PM 11/24/2021

Browser tabs: (45 unread) - rtungadi@yahoo.c... x

Address bar: mail.yahoo.com/d/search/name=Editor%2520AJPCR&emailAddresses=editorajpcr%2540gmail.com&emailAddresses=editor%2540ajpcr.com&listFilter=FRO...

Page title: Editor AJPCR

Navigation bar: HOME MAIL NEWS FINANCE SPORT ENTERTAINMENT LIFESTYLE WEATHER TV MORE...

Search bar: Editor AJPCR Add keywords

User profile: robert

Compose button

Left sidebar:

- Inbox (45)
- Unread
- Starred
- Drafts (12)
- Sent
- Archive
- Spam
- Deleted Items

Action bar:

- Back
- Archive
- Move
- Delete
- Spam

Revision Points :-

For revision of your article see the following points

- Format:- Headings and subheading should not be numbered.
- Abbreviations:- At the first appearance in the abstract and the text, abbreviations should be preceded by words for which they stand.
- Abstract: Rewrite Abstract which should be structural (Divide it into- Objective, Methods, Results, and Conclusion).
- Symbol and units: It should be as per International System of Units (SI). See it in instructions to authors and follow accordingly and strictly.
- Equation tools should be used for formula/equation writing.
- Errors: Grammatical and punctuation errors should be rectified. Authors are suggested to use smart tools like 1 checker, ginger, grammarly, white smoke, etc.
- Most of the words are sticked, rectified it strictly.
- Insert Table(s) and Figure(s) in Result and Discussion Section at

Taskbar:

- Windows Start button
- Taskbar icons: File Explorer, Microsoft Word, Microsoft Edge, Google Chrome, Adobe Reader, etc.
- System tray: 7:12 PM 11/24/2021

(45 unread) - rtungadi@yahoo.co

mail.yahoo.com/d/search/name=Editor%2520AJPCR&emailAddresses=editorajpcr%2540gmail.com&emailAddresses=editor%2540ajpcr.com&listFilter=FRO...

Apps UDDT-Submission [New Tab] Sistem Informasi M... Reading list

HOME MAIL NEWS FINANCE SPORT ENTERTAINMENT LIFESTYLE WEATHER TV MORE...

yahoo!mail Editor AJPCR Add keywords robert

Compose

Inbox 45
Unread
Starred
Drafts 12
Sent
Archive
Spam
Deleted Items

Back Archive Move Delete Spam

smoke, etc.

- Most of the words are sticked, rectified it strictly.
- Insert Table(s) and Figure(s) in Result and Discussion Section at appropriate place.
- Headings of table (s) and figure (s) should be rectified. See latest issue of AJPCR.
- Table: Column headings should be in sentence case and bold. See latest issue of AJPCR.
- Fig: Ensure that titles at x and y axis are in sentence case and bold.
- Reference citation- References are to be cited in parentheses/Square bracket like [1] in line with text.
- Ensure citation of references as [1, 2] in case of 2 references and [1-3] in case of more than 2 references. Few other examples include [1, 2, 3-5, 6].
- References: References are out of format. Uniformity must be ensured in all the references. It should be made strictly as per Instructions to

7:13 PM 11/24/2021

Browser tabs: (45 unread) - rtungadi@yahoo.c... x

Address bar: mail.yahoo.com/d/search/name=Editor%2520AJPCR&emailAddresses=editorajpcr%2540gmail.com&emailAddresses=editor%2540ajpcr.com&listFilter=FRO...

Navigation bar: HOME MAIL NEWS FINANCE SPORT ENTERTAINMENT LIFESTYLE WEATHER TV MORE...

Header: yahoo!mail Editor AJPCR Add keywords robert

Compose button

Left sidebar:

- Inbox (45)
- Unread
- Starred
- Drafts (12)
- Sent
- Archive
- Spam
- Deleted Items

Toolbar: Back, Archive, Move, Delete, Spam, etc.

Email content:

etc.

- Introduction: What is rationale and novelty of study? It should be mentioned.
- Results of same data have been given by table as well as by figures. Use only one mode table or figure.
- Results should be expressed in $\text{mean} \pm \text{SD/SEM}$. Sample size and proper foot notes should be mentioned below tables.
- Error bars should be included in the figure(s). Sample size and proper foot notes should be mentioned below figure(s).
- Discussion could not be found. Only results have been given. Authors should make comparison with previously reported such works to emphasize importance of the presented work.
- Authors should add/replace at least 2 references from International Journal of Pharmacy and Pharmaceutical Sciences and may be at least one from IJAP, IJCPR and JCR etc.

Taskbar: Windows, Edge, Word, PowerPoint, etc. 7:13 PM 11/24/2021

Browser tabs: (45 unread) - rtungadi@yahoo.co... x

Address bar: mail.yahoo.com/d/search/name=Editor%2520AJPCR&emailAddresses=editorajpcr%2540gmail.com&emailAddresses=editor%2540ajpcr.com&listFilter=FRO...

Navigation bar: HOME MAIL NEWS FINANCE SPORT ENTERTAINMENT LIFESTYLE WEATHER TV MORE...

Header: yahoo!mail Editor AJPCR Add keywords robert

Compose button

Left sidebar:

- Inbox (45)
- Unread
- Starred
- Drafts (12)
- Sent
- Archive
- Spam
- Deleted Items

Toolbar: Back, Archive, Move, Delete, Spam, ...

Email content:

(All the changes made must be highlighted with RED coloured fonts or it should be done in track change mode).

Address

Asian Journal of Pharmaceutical and clinical research
MS INNOVARE ACADEMIC SCIENCES PRIVATE LIMITED
B-11, Housing Colony, Infront of Bima Hospital
Mandsaur-458001
Madhya Pradesh, India

With Best Regards
Editorial Team
Asian Journal of Pharmaceutical and clinical research

Taskbar: Windows, Edge, Word, PowerPoint, Excel, Outlook, Chrome, PDF Reader, 7:13 PM 11/24/2021

**THE EFFECT OF SEA CUCUMBER (*HOLOTHURIA SCABRA*) EXTRACT
AS HEPATOPROTECTIVE: HISTOPATHOLOGICAL STUDY**

Comment [T1]: I replace profile with effect.
Please use this title.

WIDY SUSANTI ABDULKADIR^{1*}, ROBERT TUNGADI¹

**¹Department of Pharmacy, Faculty of Sport and Health, State University of Gorontalo,
Gorontalo, Indonesia**

***Corresponding Author;**

WidySusantiAbdulkadir

Pharmacy Department, Faculty of Sport and Health

State University of Gorontalo, Indonesia

Andalas Street No. 44, Gorontalo City

HpNumber : +628124100360

E-mail address : widisusanti553@yahoo.co.id

ABSTRACT

Objective: Sea cucumber (*Holothuriascabra*) is one of the marine animals that can be consumed as food and also efficacious as a drug. One of the benefits of sea cucumber has high cell regeneration ability. This study aims to see the profile of hepatoprotective histology of sea cucumber extract on mice that have been given paracetamol toxic dose.

Methods: This experiment was conducted by using experimental animal grouped of mice which were divided into 6 groups: group I: sea cucumber extract 1%, group II: 1000 mg/kg BW or 25 mg/25 g BW, group III: 750 mg/kg BW or 18.75 mg/25 g BW, group IV: 500 mg/kg BW or 12.5 mg/25 g BW, group V: positive control (Curcuma tablet 2.5 mg/25 g BW), and group VI: paracetamol group (62.5 mg/25 g BW). The histopathology test was performed to see the improvement of liver necrosis of mice.

Results: The results of histopathological study showed that all groups of mice livers experienced necrosis (cell damage) and abnormalities. In the group of sea cucumber extract having dose 500 mg/kg BW, liver cells experienced degeneration of fat and hemorrhage as in the group of curcuma tablet, but in group 6 (paracetamol group), liver of mice experienced apoptosis (cell death). In the histopathology test results can also be seen that in group 4 at doses of 500 mg/kg BW, the liver experienced slightly less severity than all other groups.

Conclusion: The sea cucumber at doses of 500 mg/kg BW can improve the hepatic damage on mice induced by paracetamol.

Keywords: sea cucumber, hepatoprotective effect, histopathology test, mice, liver

INTRODUCTION

Liver is an intermediary organ between the digestive system and blood. One of the important functions of the liver is to protect the body against the occurrence of accumulation of harmful substances such as drugs that inserted into body from outside. Many of drugs are fat soluble and not easily excreted through urine, so that the enzyme system in the liver microsomes will do biotransformation in such way to form a metabolite which is more soluble in water and can be excreted through the urine [1]. Regarding this phenomenon, it is not surprising that the liver has possibilities to be damaged by the drugs. Generally, hepatitis due to drugs does not cause permanent damage, but sometimes it can persist and has fatal effect. Hepatotoxic is a chemical causing some toxic effects on liver cells [2]. With the excessive doses (toxic doses) or long-term retreating, this compound can cause an acute or chronic liver damage [3].

The management of liver disease is still a challenge to modern medicine as there is no effective drug available that stimulates liver function, offer protection to the liver from damage or help to regenerate hepatic cells. The only drugs available are Corticosteroids and Immunosuppressive agents. However, these suffer with several adverse effects. It is therefore necessary to search for alternative drugs for the treatment of liver diseases to replace currently used drugs of doubtful efficacy and safety [4]. In the present day scenario, nearly half of the agents used in liver diseases are either natural products or derivatives of natural products due to their ability to act on various biological targets, so there remains a great interest in the search for natural products from plants, terrestrial and marine animals and microorganisms as potential drug chemical leads for the treatment of a liver disease. Among the wide range of natural

Comment [T2]: I already delete some sentences in paragraph one. Please use this introduction

sources, herbal and marine source play a key role, where 65% of patients in US and Europe depend on herbal preparations for the treatment of liver diseases [5].

Utilization of natural materials as a traditional medicine began to be developed and testing has also been done to obtain more satisfactory results in terms of treatment and the side effects. Sea cucumber (*Holothuriscabra*) is marine biota which is widely used as a traditional medicine. Sea cucumber contains antibacterial, antifungal, antitumor and anticoagulant ingredients. Zancan and Mourao's, 2004 described that in addition to wound healing, sea cucumber extract also contained anticoagulant and antithrombotic compounds [6]. The research that has been done by Latifah and Widysusanti, 2010 illustrated that at a concentration of 35%, sea cucumber suspension had hepatoprotective effect and improved liver tissue [7].

Meanwhile, Nurhidayati, 2010 stated that sand cucumber was capable of preventing damage to hepatocytes induced by carbon tetrachloride and the highest protective effect was obtained at a dose of 50 mg/200 g body weight of the experimental animal. However, there is no real correlation between increasing doses of the sand cucumber with its hepatoprotective effect against carbon tetrachloride. In addition, Novrita and Nurhidayati, 2016 described that *Holothuriscabra* can improve liver fibrosis in mice induced by carbon tetrachloride. Regarding this, Widysusanti and Robert, 2017 found that sea cucumber (*Holothuriscabra*) extract at a concentration of 1% can improve the severity level of hepatic damage in mice by reducing the parameter of SGPT and SGOT⁸. Therefore, in this research was continued by describing histopathological study of sea cucumber extract as hepatoprotective effect.

MATERIALS AND METHODS

Materials

Sea cucumber (*Holothuriscabra*) was derived from Wajo Village, Tilamuta, Boalemo, Gorontalo, Indonesia.

Extraction of sea cucumber

The sea cucumber samples were processed by splitting and removing the stomach contents and then washed with clean water until it were clean and free of dirt, then it were cut into small pieces and dried for 2 weeks under the direct sunlight. The dried sample then put into a container of maceration and soaked with methanol until surface of all sea cucumber was completely immersed. The result then stirred every day 3 times and the solvent was replaced every 3 days with the same treatment. The extracted solution from the first day to the last day (on the 15th day) was mixed to be evaporated until it produced a viscous sea cucumber extract. The viscous extract was evaporated again at room temperature until dry and then prepared it to the next test.

Comment [T3]: Already make correction for grammar

Preparation of Na-CMC 1% Suspension

The Na-CMC suspension was prepared by dissolving approximately 1.0 g of Na-CMC that had been carefully weighed into 100 ml of distilled water (which had been heated at 70°C) gradually and stirred with an electric stirrer until homogeneous suspension was formed.

Preparation of paracetamol suspension into hepatotoxic dose 250 mg/kg BW

Paracetamol was suspended into 1% Na-CMC prepared by diluting 625 mg of paracetamol, that was carefully measured, into 100 mL of Na-CMC 1% (hepatotoxic paracetamol 6.25 mg/25 g dose against the mice body weight).

Preparation of dry extract of sea cucumber into Na-CMC 1% suspension

The dry extract of sea cucumber was suspended into Na-CMC 1% suspension made by dissolving the dried extract which had been weighed according to the desired concentration of 1%; 1000 mg/kg BW, 750 mg/kg BW, 500 mg/kg BW, curcuma tablet 2.5 mg/25 g BW, paracetamol group 62.5 mg/25 g BW of the mice.

Ethical consideration

Experimental protocols and procedures used in this study were approved by health ethics committee, The Faculty of Medicine, Hasanuddin University, No.325/H4.8.4.5.31/PP36-KOMETIK/2017. All the experimental procedures were carried out in accordance with international guidelines for the care and use of laboratory animals.

Test of dried sea cucumber extract as hepatoprotective effect

The treatment group of the dried sea cucumber extract (1%) was administered orally of 1 ml/25 g BW to the mice, every day for 7 consecutive days, at 30 min afterwards, paracetamol as hepatotoxic dose was administered at a dose of 62.5 mg/25 g BW mice. On the 8th day, the blood was taken and the liver surgery was performed (group 1).

This protocol was repeated the same way in the different doses for group 2 (1000 mg/Kg BW or 25 mg/25 g), group 3 (750 mg/Kg BW or 18.75 mg/25 g BW), group 4 (500 mg/Kg BW or 12.5 mg/25 g BW), group 5 (2.5 mg/g BW) and group 6 (Na-CMC 1% solution 1 ml/25 gram).

Histopathological preparation from the mice liver

On the day 9th, the liver of the mice was cut with 3 mm microtome then the fixation was conducted. After that, the preparation was inserted successively into 50% ethanol solution for 30 minutes, 90% ethanol for 30 minutes, ethanol absolute for 30 minutes, each having 2 treatments [9].

The preparation then fed into paraffin-xylol, then sterilized in the oven for one hour at 60°C. The preparation was transferred into the liquid paraffin for one and a half hours into the preparatory block. In addition to print, the preparation was cut as thick as 5 microns then attached to a glass object that had been given albumin glycerin and heated 50°C until it was dry. After drying, it was put into pure xylol for 5-10 minutes. Preparations were taken and fed into ethanol solution 96%, 90%, 70% and 50% for 5-10 minutes, gradually. The preparation then

Comment [T4]: Already make correction

Comment [T5]: Already make correction for grammar

Comment [T6]: Already make correction

Comment [T7]: Already make correction

Comment [T8]: I delete reference no in the heading and I put it here

washed with water then fed into the Erlich dye solution for 5 minutes. The result was washed with clean water then put into ethanol solution gradually of 50%, 70%, 90%, 96%, and into ethanol absolute. After that, it was inserted into eosin-alcohol for 1-2 minutes then the result was rinsed into water then put into ethanol 50%, 70%, 90%, 96% then into absolute ethanol, and xylol. The preparation then dried at room temperature and covered with canned balm and glass objects then observed under a microscope.

RESULTS AND DISCUSSION

Histological test results can be seen in the **figure 1** which consisted of 6 pictures i.e. group 1 (62.5 mg/25 g BW of paracetamol dose), group 2 (1000 mg/kg BW of sea cucumber extract), group 3 (750 mg/kg BB), group 4 (500 mg/kg BW), group 5 (curcuma tablet doses of 2.5 mg/g), and group 6 (Na-CMC 1%).

This study used paracetamol induction doses of 62.5 mg/25 g given orally to induce liver cell necrosis and sea cucumber administration performed prior to paracetamol administration aimed to see the effect of liver protection by sea cucumber extract. So this study focuses on the preventive concept to see the potential of sea cucumber as a hepatoprotective material. The previous study explained that SGPT value on mice which induced paracetamol showed dose 500 mg/kg of sea cucumber extract had given hepatoprotective effect (SGPT 32 u/l) which proven by histological test [8].

From the histological test, this can be seen that all groups of mice liver experience necrosis (cell damage) and abnormalities. In the group of sea cucumber extract on doses 500 mg/kg BW, liver cells experience degeneration of fat and hemorrhage as in the group of curcuma tablet, but in group 6 (paracetamol group), liver of mice was apoptosis (cell death). In the histopathology test results also seen that in group 4 at doses of 500 mg/kg BW, the liver experience slightly less severity than all other groups.

Comment [T9]: This is addition information.
Please use this paragraph.

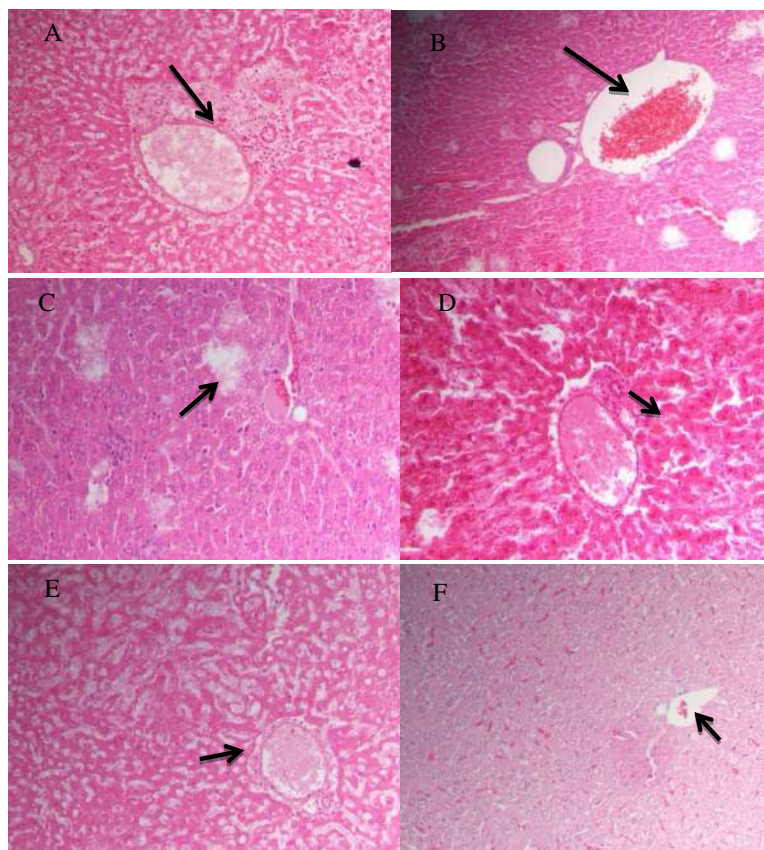


Figure 1. Photomicrograph of mice livers in the various groups: (A) group 1: paracetamol doses (62.5 mg/25 g), showing the necrosis histological structure of hepatic lobule; (B) group 2: sea cucumber extract doses (1000 mg/kg BW), showing apparent normal hepatic parenchyma (long narrow); (C) group 3: sea cucumber extract doses (750 mg/kg BW), showing lipid generation (short narrow); (D) group 4: doses of 500 mg/kg BW, showing Kupffer cell activation (short arrow); (E) group 5: curcuma tablet doses (2.5 mg/g), showing hepatocyte cell degeneration (short narrow); (F) group 6: Na-CMC 1%, showing apparent normal hepatic parenchyma (short narrow) which is similar with group 2.

Histopathologic observations described the effective doses of sea cucumber extract to prevent fatty is at a doses of 500 mg/kg BW. This is presumably because of the high protein content (86%) that is easily broken down by the enzyme pepsin, of that amount about 80% of collagen. Proteins especially amino acids, glycine and glutamate, as the main component of GSH (glutathione) is able to reuse by GSH which is exhausted due to the toxicity of paracetamol in cytoplasm and mitochondria. GSH is a robust peroxy-nitrite eliminator and prevents the effective formation of nitro-tyrosine, greatly reduces the necrosis of liver cells due to paracetamol and activates cell regeneration cycles.

This is related to Sharma et al., 2010 research stated that one of the most important antioxidant systems is the glutathione redox cycle [10, 11]. Glutathione is highly abundant in

cytosol, nuclei and mitochondria, and is the major soluble antioxidant in these cell compartments. Reduced glutathione (GSH), the main component of the endogenous nonprotein sulfhydryl pool is known to be a major low molecular weight scavenger of free radicals in the cytoplasm [12]. The depletion of GSH promotes generation of reactive oxygen species and oxidative stress with a cascade of effects, thereby affecting functional as well as the structural integrity of cell and organelle membranes [13]. The elevated level of GSH protects cellular proteins against oxidation through the glutathione redox cycle and also directly detoxifies reactive oxygen species and/or neutralizes reactive intermediate species generated from exposure to xenobiotics including chemical carcinogens [14, 15].

CONCLUSION

The extract of sea cucumber at doses of 500 mg/kg BW can improve the hepatic damage on mice induced by paracetamol.

ACKNOWLEDGEMENT

We would like to thank to the Ministry of Research and Technology of Higher Education for the support of the funds and the Head of Fisheries Department of Gorontalo Province and also Thank you for the Chairman of Commission II of the Provincial Legislative Assembly of Gorontalo for assisting to provide the sample.

AUTHORS CONTRIBUTION

Mrs. Widy S Abdulkadir - Review of literature and Data analysis. Mr. Robert - Data Collection.

CONFLICT OF INTERESTS

The authors claim that there is no conflict of interest.

REFERENCES

1. Ansari R, Dadbaksh A, Niknahad H, Heidari R, Azarpira N, Hajhashemi F. Hepatoprotective effects of Glycerrhyzeaglabra aqueous extract against carbon tetrachloride-induced liver injury in mice. Iranian J.Pharm Sci.2017;13(4):146.
2. Nair DG, Weiskirchen R, Al-musharafi SK. The Use of marine-derived bioactive compounds as potential hepatoprotective agents. Actapharmacologicasinica. 2015;36:158-70.
3. Syed SH, Namdeo AG. Current status of natural products for the treatment of liver disease-A review. Int. J. Phytopharm. 2014;4:37-43.
4. Adewusi, E.A., Afolayan, A.J. A review of natural products with hepatoprotective activity. J Med Plant Res. 2010; 4: 1318-1334.
5. Zhang, A., Sun, H., Wang, X. Recent advances in natural products from plants for treatment of liver diseases. Eur J Med Chem. 2013;63:570-77.
6. Zancan P. and P.A Mourao. Venous and arterial thrombosis in rat models: dissociation of the antitrombotic effect of glycosaminoglycans. Blood Coagul. Fibrinolysis. 2004;15:45-54.
7. Abdulkadir WS. The effect of sea cucumber suspension against hepatotoxic of paracetamol on mice: histopathological study. Thesis. Makassar: UNHAS; 2009.
8. Abdulkadir WS, Tungadi R. The hepatoprotective effect of sea cucumber (*Holothuriascabra*) extract originating from Gorontalo district using SGOT And SGPT parameters on mice induced by hepatotoxic dose of paracetamol. Int. J. ChemTech Res. 2017;10(7):105-11.
9. Fahmi SR. Anti-fibrotic effect of *Holothuriaaarenicola* extract against bile duct ligation in rats. BMC comp alter med. 2015;15:14.
10. Dakrory AI, Harbi MS, Mohamed AS. Antioxidant role of *Holothuriaatra* extract against nephrotoxicity induced by 7, 12-dimethylbenz (a) anthracene in male albino rats. Int. J. Adv Res. 2015;3(2):275-87.
11. Sharma, V & Paliwal, R. Chemo protective role of *Moringaoleifera* and its isolated saponin against DMBA induced Tissue Damage in male mice: A Histopathological analysis', Int. J. Drug Dev. Res. 2012;4(4):215-28.
12. Toklu ZH, İnac AT, Şehirli OP & Şener G. The protective effect of *Nigella sativa* oil in the brain of the biliary obstructed rats. Marmara Pharmaceut. J. 2013;17:46-51.
13. Singh RP, Padmanathi B & Rao AR. Modulatory influence of *Adhatodavesica* (*Justiciaadhatoda*) leaf extract on the enzymes of xenobiotic metabolism antioxidant status and lipid peroxidation in mice. Mol Cell Biochem. 2000;213:99-109.
14. Kettner B. Glutathione-S-transferase and prevention of cellular free radical damage. Free Rad Res. 1998;28:647-58.
15. Laksmani NP, Meiyanto EDY, Susanti RA. Cytotoxic activity of Brazilin isolated from *secang* against MCF7/Dox cells by inhibition of p-glycoprotein. Int. J. Pharm Pharm Sci. 2017;9:124-30.

Browser tabs: (45 unread) - rtungadi@yahoo.c... x

Address bar: mail.yahoo.com/d/search/name=Editor%2520AJPCR&emailAddresses=editorajpcr%2540gmail.com&emailAddresses=editor%2540ajpcr.com&listFilter=FRO...

Navigation bar: HOME MAIL NEWS FINANCE SPORT ENTERTAINMENT LIFESTYLE WEATHER TV MORE...

yahoo!mail

Search bar: Editor AJPCR Add keywords

User profile: robert

Compose

Inbox 45

Unread

Starred

Drafts 12

Sent

Archive

Spam

status/AJPCR/27747/18/Gally Proof Request 2 Yahoo/Inbox

editor ajpcr <editorajpcr@gmail.com> To: Robert Tungadi Mon, 16 July 2018 at 5:32 pm

Dear Author

Please find attached file for corrections so please resend the file after filling table .

We believe in quality and publishing on time so please read the mail

Taskbar: 27747-129904-1-....docx Show all

System tray: 7:57 PM 11/24/2021

(45 unread) - rtungadi@yahoo.c... x

mail.yahoo.com/d/search/name=Editor%2520AJPCR&emailAddresses=editorajpcr%2540gmail.com&emailAddresses=editor%2540ajpcr.com&listFilter=FRO...
Apps UDDT-Submission [New Tab] Sistem Informasi M... Reading list

HOME MAIL NEWS FINANCE SPORT ENTERTAINMENT LIFESTYLE WEATHER TV MORE...

yahoo!mail Editor AJPCR Add keywords robert

Compose

Inbox 45
Unread
Starred
Drafts 12
Sent
Archive
Spam

← Back ↶ ↷ → Archive ↗ Move Delete Spam ...

we believe in quality and publishing on time so please read the mail carefully and send the corrections within 1 days . If you are not sending corrected manuscript on time to us then it would be rejected from current issue and would be publish in next issue. We would be not be the responsible for not publishing article and publication of uncorrected article if you are not submitting in timeline.

Kindly download the galley proof for the reference no. AJPCR/27747, and if there are any possible errors of spelling, data or anything else kindly check it resend the corrected one quickly within 1 days . Mark the corrections in the pdf itself using sticky notes. (Send corrections to editor@ajpcr.com)

(Please mention your article reference no.)

27747-129904-1-....docx Show all

Windows taskbar: 7:57 PM 11/24/2021

mail.yahoo.com/d/search/name=Editor%2520AJPCR&emailAddresses=editorajpcr%2540gmail.com&emailAddresses=editor%2540ajpcr.com&listFilter=FRO...

HOME MAIL NEWS FINANCE SPORT ENTERTAINMENT LIFESTYLE WEATHER TV MORE...

yahoo!mail Editor AJPCR Add keywords robert

Compose

Inbox 45
Unread
Starred
Drafts 12
Sent
Archive
Spam

Back Archive Move Delete Spam

Please mention your article reference no.

Important :- Abstract must be up to 250 words in a structured form, consisting of: Objective, Methods, Results, and Conclusion in case the not received the structured abstract the article will not be published until the abstract is structured .

Please ensure that you have reviewed your article on the base of the points given below.

1. Format:- Headings and subheading should not be numbered.
2. Abbreviations:- At the first appearance in the abstract and the text, abbreviations should be preceded by words for which they stand.
3. Abstract: Rewrite Abstract which should be structural (Divide it into- Objective, Methods, Results, and Conclusion).

27747-129904-1-....docx Show all

7:57 PM 11/24/2021

Browser tabs: (45 unread) - rtungadi@yahoo.c... x

Address bar: mail.yahoo.com/d/search/name=Editor%2520AJPCR&emailAddresses=editorajpcr%2540gmail.com&emailAddresses=editor%2540ajpcr.com&listFilter=FRO...
Apps UDDT-Submission [New Tab] Sistem Informasi M... Reading list

Navigation bar: HOME MAIL NEWS FINANCE SPORT ENTERTAINMENT LIFESTYLE WEATHER TV MORE...

yahoo!mail Editor AJPCR Add keywords robert

Compose

Inbox 45
Unread
Starred
Drafts 12
Sent
Archive
Spam

Actions: Back, Archive, Move, Delete, Spam, ...

Subject: Methods, Results, and Conclusions.

4. Symbol and units: It should be as per International System of Units (SI). See it in instructions to authors and follow accordingly and strictly.
5. Equation tools should be used for formula/equation writing.
6. Errors: Grammatical and punctuation errors should be rectified. Authors are suggested to use smart tools like 1 checker, ginger, grammarly, white smoke, etc.
7. Most of the words are sticked, rectified it strictly.
8. Insert Table(s) and Figure(s) in Result and Discussion Section at appropriate place.
9. Headings of table (s) and figure (s) should be rectified. See latest issue of AJPCR.
10. Table: Column headings should be in sentence case and bold. See latest issue of AJPCR.

Taskbar: 27747-129904-1-....docx Show all

System tray: 7:57 PM 11/24/2021

Browser tabs: (45 unread) - rtungadi@yahoo.c... x

Address bar: mail.yahoo.com/d/search/name=Editor%2520AJPCR&emailAddresses=editorajpcr%2540gmail.com&emailAddresses=editor%2540ajpcr.com&listFilter=FRO...

Navigation bar: HOME MAIL NEWS FINANCE SPORT ENTERTAINMENT LIFESTYLE WEATHER TV MORE...

Header: yahoo!mail Editor AJPCR Add keywords robert

Compose button

Left sidebar:

- Inbox (45)
- Unread
- Starred
- Drafts (12)
- Sent
- Archive
- Spam

Toolbar: Back, Archive, Move, Delete, Spam, ...

Email content:


11. Fig: Ensure that titles at x and y axis are in sentence case and bold.
12. Reference citation- References are to be cited in parentheses/Square bracket like [1] in line with text.
13. Ensure citation of references as [1, 2] in case of 2 references and [1-3] in case of more than 2 references. Few other examples include [1, 2, 3-5, 6].
14. References: References are out of format. Uniformity must be ensured in all the references. It should be made strictly as per Instructions to Authors. Journal's title should be non italic, abbreviated without use of full stop.
15. Pagination style is incorrect in references. Authors should refer any latest published article in AJPCR. Digit appeared in starting page number should not be repeated in end page number. Ex. 12-5, 25-32, 125-7, 11456-62

Taskbar: 27747-129904-1-....docx, Show all, 7:57 PM 11/24/2021

(45 unread) - rtungadi@yahoo.c... x


mail.yahoo.com/d/search/name=Editor%2520AJPCR&emailAddresses=editorajpcr%2540gmail.com&emailAddresses=editor%2540ajpcr.com&listFilter=FRO...
Apps UDDT-Submission |... f New Tab G Sistem Informasi M... Reading list

HOME MAIL NEWS FINANCE SPORT ENTERTAINMENT LIFESTYLE WEATHER TV MORE...

yahoo!mail Editor AJPCR Add keywords  robert

Compose

Inbox 45
Unread
Starred
Drafts 12
Sent
Archive
Spam

← Back ↶ ↷ → Archive ↗ Move Delete Spam ...  24

etc.
16. Introduction: What is rationale and novelty of study? It should be mentioned.
17. Results of same data have been given by table as well as by figures. Use only one mode table or figure.
18. Results should be expressed in mean±SD/SEM. Sample size and proper foot notes should be mentioned below tables.
19. Error bars should be included in the figure(s). Sample size and proper foot notes should be mentioned below figure(s).
20. Discussion could not be found. Only results have been given. Authors should make comparison with previously reported such works to emphasize importance of the presented work.

27747-129904-1-....docx Show all x

Windows taskbar: Word, Excel, PowerPoint, Edge, File Explorer, Photoshop, Teams, Chrome, Acrobat. System tray: 7:57 PM 11/24/2021

THE EFFECT OF SEA CUCUMBER (*HOLOTHURIA SCABRA*) EXTRACT AS HEPATOPROTECTIVE: HISTOPATHOLOGICAL STUDY

WIDY SUSANTI ABDULKADIR*, ROBERT TUNGADI

Department of Pharmacy, Faculty of Sport and Health, State University of Gorontalo, Gorontalo, Indonesia.

Email: widisusanti553@yahoo.co.id

Received: 06 June 2018, Revised and Accepted: 03 July 2018

ABSTRACT

Objective: Sea cucumber *Holothuria scabra* is one of the marine animals that can be consumed as food and also efficacious as a drug. One of the benefits of sea cucumber has high cell regeneration ability. This study aims to see the profile of hepatoprotective histology of sea cucumber extract on mice that have been given paracetamol toxic dose.

Methods: This experiment was conducted using experimental animal grouped of mice which were divided into six groups: Group I: sea cucumber extract 1%, Group II: 1000 mg/kg body weight (BW) or 25 mg/25 g BW, Group III: 750 mg/kg BW or 18.75 mg/25 g BW, Group IV: 500 mg/kg BW or 12.5 mg/25 g BW, Group V: positive control (curcuma tablet 2.5 mg/25 g BW), and Group VI: paracetamol group (62.5 mg/25 g BW). The histopathology test was performed to see the improvement of liver necrosis of mice.

Results: The results of histopathological study showed that all groups of mice livers experienced necrosis (cell damage) and abnormalities. In the group of sea cucumber extract having dose 500 mg/kg BW, liver cells experienced degeneration of fat and hemorrhage as in the group of curcuma tablet, but in Group VI (paracetamol group), liver of mice experienced apoptosis (cell death). In the histopathology test, results can also be seen that in Group IV at doses of 500 mg/kg BW, the liver experienced slightly less severity than all other groups.

Conclusion: The sea cucumber at doses of 500 mg/kg BW can improve the hepatic damage on mice induced by paracetamol.

Keywords: Sea cucumber, Hepatoprotective effect, Histopathology test, Mice, Liver.

© 2018 The Authors. Published by Innovare Academic Sciences Pvt Ltd. This is an open access article under the CC BY license (<http://creativecommons.org/licenses/by/4.0/>) DOI: <http://dx.doi.org/10.22159/ajpcr.2018.v11i9.27747>

INTRODUCTION

Liver is an intermediary organ between the digestive system and blood. One of the important functions of the liver is to protect the body against the occurrence of accumulation of harmful substances such as drugs that inserted into the body from outside. Many of drugs are fat soluble and not easily excreted through urine so that the enzyme system in the liver microsomes will do biotransformation in such way to form a metabolite which is more soluble in water and can be excreted through the urine [1]. Regarding this phenomenon, it is not surprising that the liver has possibilities to be damaged by the drugs. In general, hepatitis due to drugs does not cause permanent damage, but sometimes it can persist and has fatal effect. Hepatotoxic is a chemical causing some toxic effects on liver cells [2]. With the excessive doses (toxic doses) or long-term retreating, this compound can cause an acute or chronic liver damage [3].

The management of liver disease is still a challenge to modern medicine as there is no effective drug available that stimulates liver function, offer protection to the liver from damage or help to regenerate hepatic cells. The only drugs available are corticosteroids and immunosuppressive agents. However, these suffer with several adverse effects. It is, therefore, necessary to search for alternative drugs for the treatment of liver diseases to replace currently used drugs of doubtful efficacy and safety [4]. In the present day scenario, nearly half of the agents used in liver diseases are either natural products or derivatives of natural products due to their ability to act on various biological targets, so there remains a great interest in the search for natural products from plants, terrestrial, and marine animals and microorganisms as potential drug chemical leads for the treatment of a liver disease. Among the wide range of natural sources, herbal and marine source play a key role, where 65% of patients in US and Europe depend on herbal preparations for the treatment of liver diseases [5].

Utilization of natural materials as a traditional medicine began to be developed, and testing has also been done to obtain more satisfactory results in terms of treatment and the side effects. Sea cucumber *Holothuria scabra* is marine biota which is widely used as a traditional medicine. Sea cucumber contains antibacterial, antifungal, antitumor, and anticoagulant ingredients. Zancan and Mourao's, 2004, described that in addition to wound healing, sea cucumber extract also contained anticoagulant and antithrombotic compounds [6]. The research that has been done by Abdulkadir, 2010, illustrated that at a concentration of 35%, sea cucumber suspension had hepatoprotective effect and improved liver tissue [7].

Meanwhile, Nurhidayati, 2010, stated that sand cucumber was capable of preventing damage to hepatocytes induced by carbon tetrachloride and the highest protective effect was obtained at a dose of 50 mg/200 g body weight (BW) of the experimental animal. However, there is no real correlation between increasing doses of the sand cucumber with its hepatoprotective effect against carbon tetrachloride. In addition, Novrita and Nurhidayati, 2016, described that *H. scabra* can improve liver fibrosis in mice induced by carbon tetrachloride. Regarding this, Abdulkadir and Tungadi, 2017, found that sea cucumber *H. scabra* extract at a concentration of 1% can improve the severity level of hepatic damage in mice by reducing the parameter of serum glutamate pyruvic transaminase (SGPT) and serum glutamic oxaloacetic transaminase [8]. Therefore, in this research was continued by describing histopathological study of sea cucumber extract as hepatoprotective effect.

MATERIALS AND METHODS

Materials

Sea cucumber *H. scabra* was derived from Wajo village, Tilamuta, Boalemo, Gorontalo, Indonesia.

Extraction of sea cucumber

The sea cucumber samples were processed by splitting and removing the stomach contents and then washed with clean water until it was clean and free of dirt, then it was cut into small pieces and dried for 2 weeks under the direct sunlight. The dried sample then put into a container of maceration and soaked with methanol until the surface of all sea cucumber was completely immersed. The result then stirred every day 3 times, and the solvent was replaced every 3 days with the same treatment. The extracted solution from the first day to the last day (on the 15th day) was mixed to be evaporated until it produced a viscous sea cucumber extract. The viscous extract was evaporated again at room temperature until dry and then prepared it to the next test.

Preparation of Na-carboxymethyl cellulose (CMC) 1% suspension

The Na-CMC suspension was prepared by dissolving approximately 1.0 g of Na-CMC that had been carefully weighed into 100 ml of distilled water (which had been heated at 70°C) gradually and stirred with an electric stirrer until homogeneous suspension was formed.

Preparation of paracetamol suspension into hepatotoxic dose 250 mg/kg BW

Paracetamol was suspended into 1% Na-CMC prepared by diluting 625 mg of paracetamol that was carefully measured into 100 mL of Na-CMC 1% (hepatotoxic paracetamol 6.25 mg/25 g dose against the mice BW).

Preparation of dry extract of sea cucumber into Na-CMC 1% suspension

The dry extract of sea cucumber was suspended into Na-CMC 1% suspension made by dissolving the dried extract which had been weighed according to the desired concentration of 1%; 1000 mg/kg BW, 750 mg/kg BW, 500 mg/kg BW, curcuma tablet 2.5 mg/25 g BW, and paracetamol group 62.5 mg/25 g BW of the mice.

Ethical consideration

Experimental protocols and procedures used in this study were approved by Health Ethics Committee, The Faculty of Medicine, Hasanuddin University, No.325/H4.8.4.5.31/PP36-KOMETIK/2017. All the experimental procedures were carried out in accordance with international guidelines for the care and use of laboratory animals.

Test of dried sea cucumber extract as hepatoprotective effect

The treatment group of the dried sea cucumber extract (1%) was administered orally of 1 ml/25 g BW to the mice, every day for 7 consecutive days, at 30 min afterward, paracetamol as hepatotoxic dose was administered at a dose of 62.5 mg/25 g BW mice. On the 8th day, the blood was taken, and the liver surgery was performed (Group I).

This protocol was repeated the same way in the different doses for Group II (1000 mg/kg BW or 25 mg/25 g), Group III (750 mg/kg BW or 18.75 mg/25 g BW), Group IV (500 mg/kg BW or 12.5 mg/25 g BW), Group V (2.5 mg/g BW), and Group VI (Na-CMC 1% solution 1 ml/25 g).

Histopathological preparation from the mice liver

On the day 9th, the liver of the mice was cut with 3-mm microtome then the fixation was conducted. After that, the preparation was inserted successively into 50% ethanol solution for 30 min, 90% ethanol for 30 min, and ethanol absolute for 30 min, each having two treatments [9].

The preparation then fed into paraffin-xylol, then sterilized in the oven for 1 h at 60°C. The preparation was transferred into the liquid paraffin for 1½ h into the preparatory block. In addition to print, the preparation was cut as thick as 5 microns then attached to a glass object that had been given albumin glycerin and heated at 50°C until it was dry. After drying, it was put into pure xylol for 5–10 min. Preparations were taken and fed into ethanol solution 96%, 90%, 70%, and 50% for 5–10 min, gradually. The preparation then washed with water then fed into the Ehrlich dye solution for 5 min. The result was washed with clean water then put into ethanol solution gradually of 50%, 70%, 90%, and 96% and into ethanol absolute. After that, it was inserted into eosin-alcohol

for 1–2 min; then, the result was rinsed into water then put into ethanol 50%, 70%, 90%, and 96% then into absolute ethanol and xylol. The preparation then dried at room temperature and covered with canned balm and glass objects then observed under a microscope.

RESULTS AND DISCUSSION

Histological test results can be seen in the Fig. 1 which consisted of six pictures, that is, Group I (62.5 mg/25 g BW of paracetamol dose), Group II (1000 mg/kg BW of sea cucumber extract), Group III (750 mg/kg BW), Group IV (500 mg/kg BW), Group V (curcuma tablet doses of 2.5 mg/g), and Group VI (Na-CMC 1%).

This study used paracetamol induction doses of 62.5 mg/25 g given orally to induce liver cell necrosis and sea cucumber administration performed before paracetamol administration aimed to see the effect of liver protection by sea cucumber extract. Hence, this study focuses on the preventive concept to see the potential of sea cucumber as a hepatoprotective material. The previous study explained that SGPT value on mice which induced paracetamol showed dose 500 mg/kg of sea cucumber extract had given hepatoprotective effect (SGPT 32 u/l) which proven by histological test [8].

From the histological test, this can be seen that all groups of mice liver experience necrosis (cell damage) and abnormalities. In the group of sea cucumber extract on doses 500 mg/kg BW, liver cells experience degeneration of fat and hemorrhage as in the group of curcuma tablet, but in Group VI (paracetamol group), liver of mice was apoptosis (cell death). In the histopathology test results also seen that in Group IV at

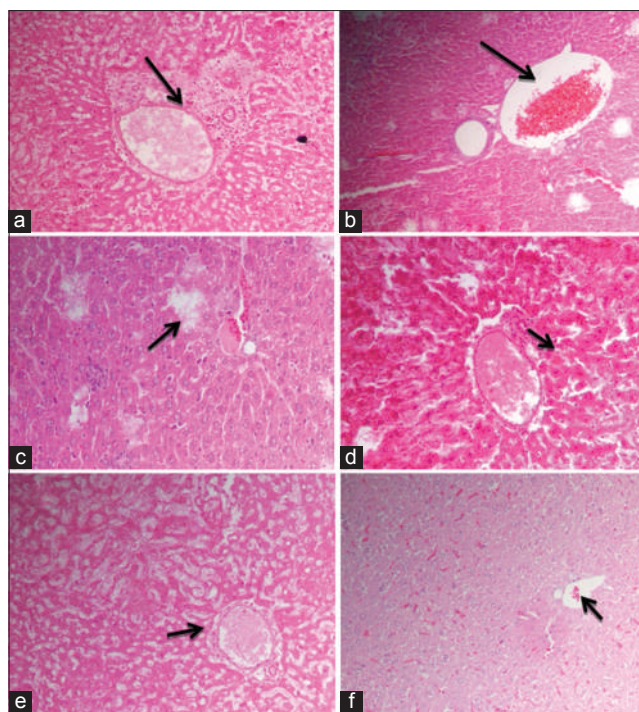


Fig. 1: Photomicrograph of mice livers in the various groups: (a) Group I: Paracetamol doses (62.5 mg/25 g) showing the necrosis histological structure of hepatic lobule; (b) Group II: Sea cucumber extract doses (1000 mg/kg BW) showing apparent normal hepatic parenchyma (long narrow); (c) Group III: Sea cucumber extract doses (750 mg/kg BW) showing lipid generation (short narrow); (d) Group IV: Doses of 500 mg/kg BW showing Kupffer cell activation (short arrow); (e) Group V: Curcuma tablet doses (2.5 mg/g) showing hepatocyte cell degeneration (short narrow); and (f) Group VI: Na-CMC 1% showing apparent normal hepatic parenchyma (short narrow) which is similar with Group II

doses of 500 mg/kg BW, the liver experience slightly less severity than all other groups.

Histopathologic observations described the effective doses of sea cucumber extract to prevent fatty is at a dose of 500 mg/kg BW. This is presumably because of the high protein content (86%) that is easily broken down by the enzyme pepsin, of that amount about 80% of collagen. Proteins, especially amino acids, glycine, and glutamate, as the main component of glutathione (GSH) are able to reuse by GSH which is exhausted due to the toxicity of paracetamol in cytoplasm and mitochondria. GSH is a robust peroxy-nitrite eliminator and prevents the effective formation of nitro-tyrosine, greatly reduces the necrosis of liver cells due to paracetamol and activates cell regeneration cycles.

This is related to Sharma and Paliwal 2010 research stated that one of the most important antioxidant systems is the GSH redox cycle [10,11]. GSH is highly abundant in cytosol, nuclei, and mitochondria and is the major soluble antioxidant in these cell compartments. Reduced GSH, the main component of the endogenous non-protein sulfhydryl pool is known to be a major low-molecular-weight scavenger of free radicals in the cytoplasm [12]. The depletion of GSH promotes the generation of reactive oxygen species and oxidative stress with a cascade of effects, thereby affecting functional as well as the structural integrity of cell and organelle membranes [13]. The elevated level of GSH protects cellular proteins against oxidation through the GSH redox cycle and also directly detoxifies reactive oxygen species and/or neutralizes reactive intermediate species generated from exposure to xenobiotics including chemical carcinogens [14,15].

CONCLUSION

The extract of sea cucumber at doses of 500 mg/kg BW can improve the hepatic damage on mice induced by paracetamol.

ACKNOWLEDGMENT

We would like to thank to the Ministry of Research and Technology of higher education for the support of the funds and the Head of Fisheries Department of Gorontalo Province and also thank you for the Chairman of Commission II of the provincial legislative assembly of Gorontalo for assisting to provide the sample.

AUTHOR'S CONTRIBUTION

Mrs. Widy S Abdulkadir - Review of literature and data analysis.
Mr. Robert - Data collection.

CONFLICTS OF INTEREST

The authors claim that there are no conflicts of interest.

REFERENCES

1. Ansari R, Dadbaksh A, Niknahad H, Heidari R, Azarpira N, Hajhashemi F. Hepatoprotective effects of *Glycyrrhiza aglabra* aqueous extract against carbon tetrachloride-induced liver injury in mice. Iran J Pharm Sci 2017;13:146.
2. Nair DG, Weiskirchen R, Al-musharafi SK. The use of marine-derived bioactive compounds as potential hepatoprotective agents. Acta Pharmacol Sin 2015;36:158-70.
3. Syed SH, Namdeo AG. Current status of natural products for the treatment of liver disease - A review. Int J Phytopharm 2014;4:37-43.
4. Adewusi EA, Afolayan AJ. A review of natural products with hepatoprotective activity. J Med Plant Res 2010;4:1318-34.
5. Zhang A, Sun H, Wang X. Recent advances in natural products from plants for treatment of liver diseases. Eur J Med Chem 2013;63:570-7.
6. Zancan P, Mourao PA. Venous and arterial thrombosis in rat models: Dissociation of the antithrombotic effect of glycosaminoglycans. Blood Coagul Fibrinolysis 2004;15:45-54.
7. Abdulkadir WS. The Effect of Sea Cucumber Suspension against Hepatotoxic of Paracetamol on Mice: Histopathological Study. Thesis. Makassar: UNHAS; 2009.
8. Abdulkadir WS, Tungadi R. The hepatoprotective effect of sea cucumber (*Holothuria scabra*) extract originating from Gorontalo district using SGOT and SGPT parameters on mice induced by hepatotoxic dose of paracetamol. Int J ChemTech Res 2017;10:105-11.
9. Fahmi SR. Anti-fibrotic effect of *Holothuria arenicola* extract against bile duct ligation in rats. BMC Comp Alter Med 2015;15:14.
10. Dakrory AI, Harbi MS, Mohamed AS. Antioxidant role of *Holothuria atra* extract against nephrotoxicity induced by 7, 12-dimethylbenz (a) anthracene in male albino rats. Int J Adv Res 2015;3:275-87.
11. Sharma V, Paliwal R. Chemo protective role of *Moringa oleifera* and its isolated saponin against DMBA induced tissue damage in male mice: A histopathological analysis'. Int J Drug Dev Res 2012;4:215-28.
12. Toklu ZH, İnac AT, Şehirli OP, Şener G. The protective effect of *Nigella sativa* oil in the brain of the biliary obstructed rats. Marmara Pharmaceut J 2013;17:46-51.
13. Singh RP, Padmanathi B, Rao AR. Modulatory influence of *Adhatoda vesica* (*Justicia adhatoda*) leaf extract on the enzymes of xenobiotic metabolism antioxidant status and lipid peroxidation in mice. Mol Cell Biochem 2000;213:99-109.
14. Kettner B. Glutathione-S-transferase and prevention of cellular free radical damage. Free Rad Res 1998;28:647-58.
15. Laksmiani NP, Meiyanto ED, Susanti RA. Cytotoxic activity of Brazilian isolated from secang against MCF7/Dox cells by inhibition of p-glycoprotein. Int J Pharm Pharm Sci 2017;9:124-30.

THE EFFECT OF SEA CUCUMBER (HOLOTHURIA SCABRA) EXTRACT AS HEPATOPROTECTIVE: HISTOPATHOLOGICAL STUDY

WIDY SUSANTI ABDULKADIR*, ROBERT TUNGADI

Department of Pharmacy, Faculty of Sport and Health, State University of Gorontalo, Gorontalo, Indonesia.

Email: widisusanti553@yahoo.co.id

Received: 06 June 2018, Revised and Accepted: 03 July 2018

ABSTRACT

Objective: Sea cucumber *Holothuria scabra* is one of the marine animals that can be consumed as food and also efficacious as a drug. One of the benefits of sea cucumber has high cell regeneration ability. This study aims to see the profile of hepatoprotective histology of sea cucumber extract on mice that have been given paracetamol toxic dose.

Methods: This experiment was conducted using experimental animal grouped of mice which were divided into six groups: Group I: sea cucumber extract 1%, Group II: 1000 mg/kg body weight (BW) or 25 mg/25 g BW, Group III: 750 mg/kg BW or 18.75 mg/25 g BW, Group IV: 500 mg/kg BW or 12.5 mg/25 g BW, Group V: positive control (curcuma tablet 2.5 mg/25 g BW), and Group VI: paracetamol group (62,5 mg/25 g BW). The histopathology test was performed to see the improvement of liver necrosis of mice.

Results: The results of histopathological study showed that all groups of mice livers experienced necrosis (cell damage) and abnormalities. In the group of sea cucumber extract having dose 500 mg/kg BW, liver cells experienced degeneration of fat and hemorrhage as in the group of curcuma tablet, but in Group VI (paracetamol group), liver of mice experienced apoptosis (cell death). In the histopathology test, results can also be seen that in Group IV at doses of 500 mg/kg BW, the liver experienced slightly less severity than all other groups.

Conclusion: The sea cucumber at doses of 500 mg/kg BW can improve the hepatic damage on mice induced by paracetamol.

Keywords: Sea cucumber, Hepatoprotective effect, Histopathology test, Mice, Liver.

© 2018 The Authors. Published by Innovare Academic Sciences Pvt Ltd. This is an open access article under the CC BY license (<http://creativecommons.org/licenses/by/4.0/>) DOI: <http://dx.doi.org/10.22159/ajpcr.2018.v11i9.27747>

INTRODUCTION

Liver is an intermediary organ between the digestive system and blood. One of the important functions of the liver is to protect the body against the occurrence of accumulation of harmful substances such as drugs that inserted into the body from outside. Many of drugs are fat soluble and not easily excreted through urine so that the enzyme system in the liver microsomes will do biotransformation in such way to form a metabolite which is more soluble in water and can be excreted through the urine [1]. Regarding this phenomenon, it is not surprising that the liver has possibilities to be damaged by the drugs. In general, hepatitis due to drugs does not cause permanent damage, but sometimes it can persist and has fatal effect. Hepatotoxic is a chemical causing some toxic effects on liver cells [2]. With the excessive doses (toxic doses) or long-term retreating, this compound can cause an acute or chronic liver damage [3].

The management of liver disease is still a challenge to modern medicine as there is no effective drug available that stimulates liver function, offer protection to the liver from damage or help to regenerate hepatic cells. The only drugs available are corticosteroids and immunosuppressive agents. However, these suffer with several adverse effects. It is, therefore, necessary to search for alternative drugs for the treatment of liver diseases to replace currently used drugs of doubtful efficacy and safety [4]. In the present day scenario, nearly half of the agents used in liver diseases are either natural products or derivatives of natural products due to their ability to act on various biological targets, so there remains a great interest in the search for natural products from plants, terrestrial, and marine animals and microorganisms as potential drug chemical leads for the treatment of a liver disease. Among the wide range of natural sources, herbal and marine source play a key role, where 65% of patients in US and Europe depend on herbal preparations for the treatment of liver diseases [5].

Utilization of natural materials as a traditional medicine began to be developed, and testing has also been done to obtain more satisfactory results in terms of treatment and the side effects. Sea cucumber *Holothuria scabra* is marine biota which is widely used as a traditional medicine. Sea cucumber contains antibacterial, antifungal, antitumor, and anticoagulant ingredients. Zancan and Mourao's, 2004, described that in addition to wound healing, sea cucumber extract also contained anticoagulant and antithrombotic compounds [6]. The research that has been done by Abdulkadir, 2010, illustrated that at a concentration of 35%, sea cucumber suspension had hepatoprotective effect and improved liver tissue [7].

Meanwhile, Nurhidayati, 2010, stated that sand cucumber was capable of preventing damage to hepatocytes induced by carbon tetrachloride and the highest protective effect was obtained at a dose of 50 mg/200 g body weight (BW) of the experimental animal. However, there is no real correlation between increasing doses of the sand cucumber with its hepatoprotective effect against carbon tetrachloride. In addition, Novrita and Nurhidayati, 2016, described that *H. scabra* can improve liver fibrosis in mice induced by carbon tetrachloride. Regarding this, Abdulkadir and Tungadi, 2017, found that sea cucumber *H. scabra* extract at a concentration of 1% can improve the severity level of hepatic damage in mice by reducing the parameter of serum glutamate pyruvic transaminase (SGPT) and serum glutamic oxaloacetic transaminase [8]. Therefore, in this research was continued by describing histopathological study of sea cucumber extract as hepatoprotective effect.

MATERIALS AND METHODS

Materials

Sea cucumber *H. scabra* was derived from Wajo village, Tilamuta, Boalemo, Gorontalo, Indonesia.

Extraction of sea cucumber

The sea cucumber samples were processed by splitting and removing the stomach contents and then washed with clean water until it was clean and free of dirt, then it was cut into small pieces and dried for 2 weeks under the direct sunlight. The dried sample then put into a container of maceration and soaked with methanol until the surface of all sea cucumber was completely immersed. The result then stirred every day 3 times, and the solvent was replaced every 3 days with the same treatment. The extracted solution from the first day to the last day (on the 15th day) was mixed to be evaporated until it produced a viscous sea cucumber extract. The viscous extract was evaporated again at room temperature until dry and then prepared it to the next test.

Preparation of Na-carboxymethyl cellulose (CMC) 1% suspension

The Na-CMC suspension was prepared by dissolving approximately 1.0 g of Na-CMC that had been carefully weighed into 100 ml of distilled water (which had been heated at 70°C) gradually and stirred with an electric stirrer until homogeneous suspension was formed.

Preparation of paracetamol suspension into hepatotoxic dose 250 mg/kg BW

Paracetamol was suspended into 1% Na-CMC prepared by diluting 625 mg of paracetamol that was carefully measured into 100 mL of Na-CMC 1% (hepatotoxic paracetamol 6.25 mg/25 g dose against the mice BW).

Preparation of dry extract of sea cucumber into Na-CMC 1% suspension

The dry extract of sea cucumber was suspended into Na-CMC 1% suspension made by dissolving the dried extract which had been weighed according to the desired concentration of 1%; 1000 mg/kg BW, 750 mg/kg BW, 500 mg/kg BW, curcuma tablet 2.5 mg/25 g BW, and paracetamol group 62.5 mg/25 g BW of the mice.

Ethical consideration

Experimental protocols and procedures used in this study were approved by Health Ethics Committee, The Faculty of Medicine, Hasanuddin University, No.325/H4.8.4.5.31/PP36-KOMETIK/2017. All the experimental procedures were carried out in accordance with international guidelines for the care and use of laboratory animals.

Test of dried sea cucumber extract as hepatoprotective effect

The treatment group of the dried sea cucumber extract (1%) was administered orally of 1 ml/25 g BW to the mice, every day for 7 consecutive days, at 30 min afterward, paracetamol as hepatotoxic dose was administered at a dose of 62.5 mg/25 g BW mice. On the 8th day, the blood was taken, and the liver surgery was performed (Group I).

This protocol was repeated the same way in the different doses for Group II (1000 mg/kg BW or 25 mg/25 g), Group III (750 mg/kg BW or 18.75 mg/25 g BW), Group IV (500 mg/kg BW or 12.5 mg/25 g BW), Group V (2.5 mg/g BW), and Group VI (Na-CMC 1% solution 1 ml/25 g).

Histopathological preparation from the mice liver

On the day 9th, the liver of the mice was cut with 3-mm microtome then the fixation was conducted. After that, the preparation was inserted successively into 50% ethanol solution for 30 min, 90% ethanol for 30 min, and ethanol absolute for 30 min, each having two treatments [9].

The preparation then fed into paraffin-xylol, then sterilized in the oven for 1 h at 60°C. The preparation was transferred into the liquid paraffin for 1½ h into the preparatory block. In addition to print, the preparation was cut as thick as 5 microns then attached to a glass object that had been given albumin glycerin and heated at 50°C until it was dry. After drying, it was put into pure xylol for 5–10 min. Preparations were taken and fed into ethanol solution 96%, 90%, 70%, and 50% for 5–10 min, gradually. The preparation then washed with water then fed into the Ehrlich dye solution for 5 min. The result was washed with clean water then put into ethanol solution gradually of 50%, 70%, 90%, and 96% and into ethanol absolute. After that, it was inserted into eosin-alcohol

for 1–2 min; then, the result was rinsed into water then put into ethanol 50%, 70%, 90%, and 96% then into absolute ethanol and xylol. The preparation then dried at room temperature and covered with canned balm and glass objects then observed under a microscope.

RESULTS AND DISCUSSION

Histological test results can be seen in the Fig. 1 which consisted of six pictures, that is, Group I (62.5 mg/25 g BW of paracetamol dose), Group II (1000 mg/kg BW of sea cucumber extract), Group III (750 mg/kg BW), Group IV (500 mg/kg BW), Group V (curcuma tablet doses of 2.5 mg/g), and Group VI (Na-CMC 1%).

This study used paracetamol induction doses of 62.5 mg/25 g given orally to induce liver cell necrosis and sea cucumber administration performed before paracetamol administration aimed to see the effect of liver protection by sea cucumber extract. Hence, this study focuses on the preventive concept to see the potential of sea cucumber as a hepatoprotective material. The previous study explained that SGPT value on mice which induced paracetamol showed dose 500 mg/kg of sea cucumber extract had given hepatoprotective effect (SGPT 32 u/l) which proven by histological test [8].

From the histological test, this can be seen that all groups of mice liver experience necrosis (cell damage) and abnormalities. In the group of sea cucumber extract on doses 500 mg/kg BW, liver cells experience degeneration of fat and hemorrhage as in the group of curcuma tablet, but in Group VI (paracetamol group), liver of mice was apoptosis (cell death). In the histopathology test results also seen that in Group IV at

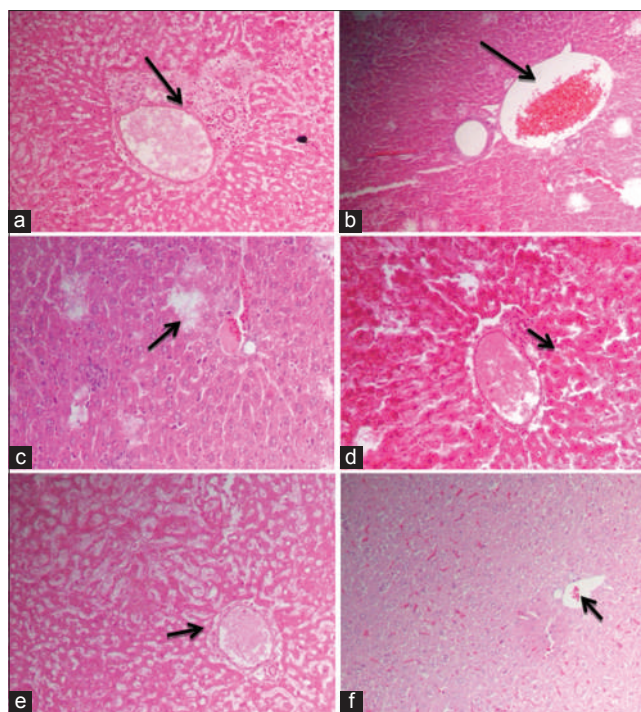


Fig. 1: Photomicrograph of mice livers in the various groups: (a) Group I: Paracetamol doses (62.5 mg/25 g) showing the necrosis histological structure of hepatic lobule; (b) Group II: Sea cucumber extract doses (1000 mg/kg BW) showing apparent normal hepatic parenchyma (long narrow); (c) Group III: Sea cucumber extract doses (750 mg/kg BW) showing lipid generation (short narrow); (d) Group IV: Doses of 500 mg/kg BW showing Kupffer cell activation (short arrow); (e) Group V: Curcuma tablet doses (2.5 mg/g) showing hepatocyte cell degeneration (short narrow); and (f) Group VI: Na-CMC 1% showing apparent normal hepatic parenchyma (short narrow) which is similar with Group II

doses of 500 mg/kg BW, the liver experience slightly less severity than all other groups.

Histopathologic observations described the effective doses of sea cucumber extract to prevent fatty is at a dose of 500 mg/kg BW. This is presumably because of the high protein content (86%) that is easily broken down by the enzyme pepsin, of that amount about 80% of collagen. Proteins, especially amino acids, glycine, and glutamate, as the main component of glutathione (GSH) are able to reuse by GSH which is exhausted due to the toxicity of paracetamol in cytoplasm and mitochondria. GSH is a robust peroxy-nitrite eliminator and prevents the effective formation of nitro-tyrosine, greatly reduces the necrosis of liver cells due to paracetamol and activates cell regeneration cycles.

This is related to Sharma and Paliwal 2010 research stated that one of the most important antioxidant systems is the GSH redox cycle [10,11]. GSH is highly abundant in cytosol, nuclei, and mitochondria and is the major soluble antioxidant in these cell compartments. Reduced GSH, the main component of the endogenous non-protein sulfhydryl pool is known to be a major low-molecular-weight scavenger of free radicals in the cytoplasm [12]. The depletion of GSH promotes the generation of reactive oxygen species and oxidative stress with a cascade of effects, thereby affecting functional as well as the structural integrity of cell and organelle membranes [13]. The elevated level of GSH protects cellular proteins against oxidation through the GSH redox cycle and also directly detoxifies reactive oxygen species and/or neutralizes reactive intermediate species generated from exposure to xenobiotics including chemical carcinogens [14,15].

CONCLUSION

The extract of sea cucumber at doses of 500 mg/kg BW can improve the hepatic damage on mice induced by paracetamol.

ACKNOWLEDGMENT

We would like to thank to the Ministry of Research and Technology of higher education for the support of the funds and the Head of Fisheries Department of Gorontalo Province and also thank you for the Chairman of Commission II of the provincial legislative assembly of Gorontalo for assisting to provide the sample.

AUTHOR'S CONTRIBUTION

Mrs. Widy S Abdulkadir - Review of literature and data analysis.
Mr. Robert - Data collection.

CONFLICTS OF INTEREST

The authors claim that there are no conflicts of interest.

REFERENCES

1. Ansari R, Dadbaksh A, Niknahad H, Heidari R, Azarpira N, Hajihashemi F. Hepatoprotective effects of *Glycyrrhiza aglabra* aqueous extract against carbon tetrachloride-induced liver injury in mice. *Iran J Pharm Sci* 2017;13:146.
2. Nair DG, Weiskirchen R, Al-musharafi SK. The use of marine-derived bioactive compounds as potential hepatoprotective agents. *Acta Pharmacol Sin* 2015;36:158-70.
3. Syed SH, Namdeo AG. Current status of natural products for the treatment of liver disease - A review. *Int J Phytopharm* 2014;4:37-43.
4. Adewusi EA, Afolayan AJ. A review of natural products with hepatoprotective activity. *J Med Plant Res* 2010;4:1318-34.
5. Zhang A, Sun H, Wang X. Recent advances in natural products from plants for treatment of liver diseases. *Eur J Med Chem* 2013;63:570-7.
6. Zancan P, Mourao PA. Venous and arterial thrombosis in rat models: Dissociation of the antithrombotic effect of glycosaminoglycans. *Blood Coagul Fibrinolysis* 2004;15:45-54.
7. Abdulkadir WS. The Effect of Sea Cucumber Suspension against Hepatotoxic of Paracetamol on Mice: Histopathological Study. Thesis. Makassar: UNHAS; 2009.
8. Abdulkadir WS, Tungadi R. The hepatoprotective effect of sea cucumber (*Holothuria scabra*) extract originating from Gorontalo district using SGOT and SGPT parameters on mice induced by hepatotoxic dose of paracetamol. *Int J ChemTech Res* 2017;10:105-11.
9. Fahmi SR. Anti-fibrotic effect of *Holothuria arenicola* extract against bile duct ligation in rats. *BMC Comp Alter Med* 2015;15:14.
10. Dakrory AI, Harbi MS, Mohamed AS. Antioxidant role of *Holothuria atra* extract against nephrotoxicity induced by 7, 12-dimethylbenz (a) anthracene in male albino rats. *Int J Adv Res* 2015;3:275-87.
11. Sharma V, Paliwal R. Chemo protective role of *Moringa oleifera* and its isolated saponin against DMBA induced tissue damage in male mice: A histopathological analysis'. *Int J Drug Dev Res* 2012;4:215-28.
12. Toklu ZH, İnac AT, Şehirli OP, Şener G. The protective effect of *Nigella sativa* oil in the brain of the biliary obstructed rats. *Marmara Pharmaceut J* 2013;17:46-51.
13. Singh RP, Padmanathi B, Rao AR. Modulatory influence of *Adhatoda vesica* (*Justicia adhatoda*) leaf extract on the enzymes of xenobiotic metabolism antioxidant status and lipid peroxidation in mice. *Mol Cell Biochem* 2000;213:99-109.
14. Kettner B. Glutathione-S-transferase and prevention of cellular free radical damage. *Free Rad Res* 1998;28:647-58.
15. Laksmiani NP, Meiyanto ED, Susanti RA. Cytotoxic activity of Brazil isolated from secang against MCF7/Dox cells by inhibition of p-glycoprotein. *Int J Pharm Pharm Sci* 2017;9:124-30.